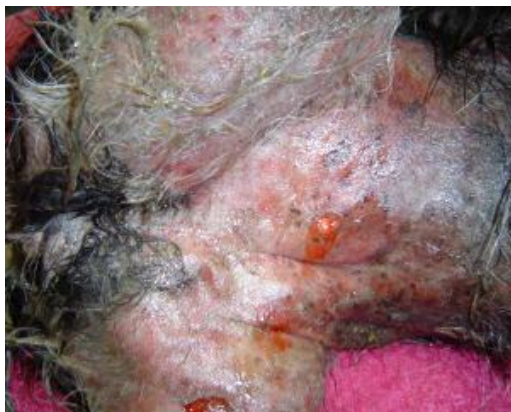


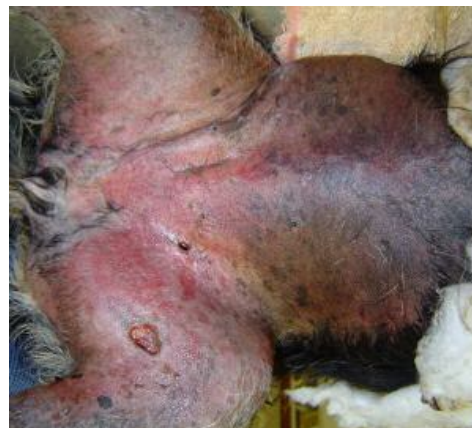
Case study: Extensive bruising after bite wounds

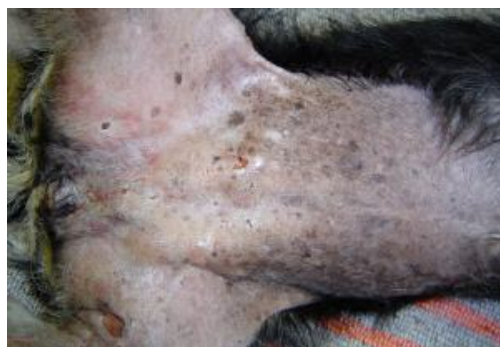- Patient:** 12 year old female dog presented in shock, severe pain, swelling and bruising after being attacked by a pack of dogs.
- Treatment:** All feared for the life of this patient, not to mention the possible necrosis and corrective surgery that was to be needed afterwards. The patient was placed on a drip, opioid analgesia and antibiotics administered systemically and phototherapy was started immediately. Phototherapy was done once a day, for 3 minutes.
- Outcome:** 24 hours and 1 phototherapy session later, the skin was still bruised but the patient was in far less pain, the skin showed no sign of necrosis and the swelling had subsided. 4 Days and 3 phototherapy sessions later the patient was almost fully recovered with no sign of bruising or necrosis.



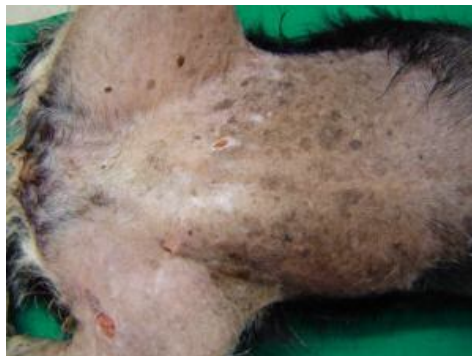
Presenting wound



12 hours and 1 phototherapy session later



4 Days and 3 phototherapy sessions later



7 Days and 5 phototherapy sessions later