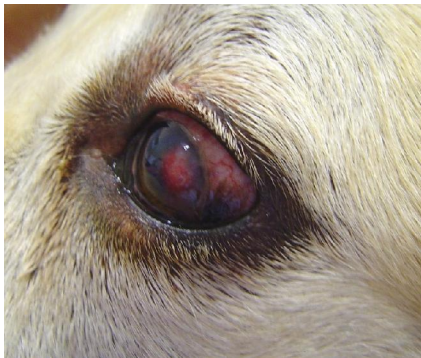

Vet - Light

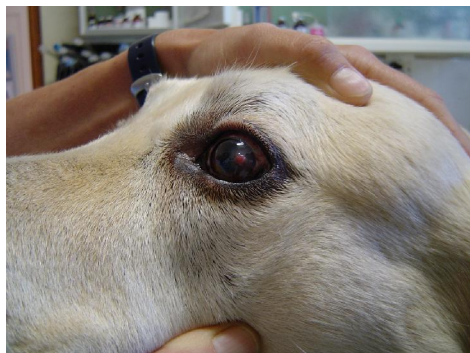


Case study: Untreated corneal ulcer

- Patient:** 8 year old, male Labrador dog
- History:** The patient was presented with an untreated ulcer on the left cornea the owners did not notice. The eye was red, inflamed and painful.
- Treatment:** Light therapy was done once a day using the **Tissue Trauma protocol**. No other medication was used during this trial.
- Outcome:** The granulation tissue and inflammation on the cornea healed without complications and much faster than initially predicted.



Presenting lesion



4 Light therapy sessions later



7 Light therapy sessions later