

Case Study 5

Venous Insufficiency 1

Patient:

71 year old female

History:

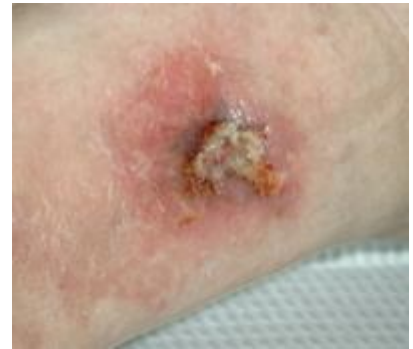Small trauma wound was treated for 86 days with isobetadine and was not healing.

Treatment:

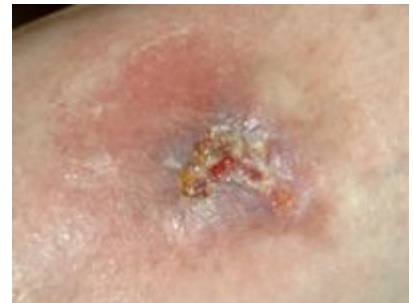
Light therapy was done for 3 minutes, once a day (betadine treatment was continued). No compression bandage was used on this patient.

Outcome:

The wound took a total of 20 days to heal with the use of light therapy whereas it was not healing before for over 2.5 months.



23/08/2006



05/09/2006